

## Radiological determination of the cranial index of present-day Ghanaians

Benard Ohene Botwe, Jeffrey Nana Afari Boadu, Kofi Adesi Kyei, John D. & Thompson

To cite this article: Benard Ohene Botwe, Jeffrey Nana Afari Boadu, Kofi Adesi Kyei, John D. & Thompson (2021): Radiological determination of the cranial index of present-day Ghanaians, *Forensic Sciences Research*, DOI: [10.1080/20961790.2021.1886680](https://doi.org/10.1080/20961790.2021.1886680)

To link to this article: <https://doi.org/10.1080/20961790.2021.1886680>



© 2021 The Author(s). Published by Taylor & Francis Group on behalf of the Academy of Forensic Science.



Published online: 31 Mar 2021.



Submit your article to this journal [↗](#)



View related articles [↗](#)



View Crossmark data [↗](#)

## Radiological determination of the cranial index of present-day Ghanaians

Benard Ohene Botwe<sup>a</sup> , Jeffrey Nana Afari Boadu<sup>a</sup>, Kofi Adesi Kyei<sup>a</sup> , John D. Thompson<sup>b</sup>

<sup>a</sup>Department of Radiography, University of Ghana School of Biomedical & Allied Health Sciences, College of Health Sciences, Accra, Ghana; <sup>b</sup>Directorate of Radiography, School of Health Sciences, University of Salford, Salford, UK

### ABSTRACT

The cranial index (CI) of Ghanaians is currently unknown. The aim of this study was to measure the CI in a population of Ghanaians in order to classify them against pre-determined CI categories. A systematic random sampling method was used to select 300 normal computed tomography (CT) head scans of adult Ghanaians from the largest hospital in Ghana. All patients were deemed to have a normal cranial image configuration based on the radiological report. The biparietal diameter (BPD, width) and the occipitofrontal diameter (OFD, length) were measured on transaxial CT images using a workstation with a calibrated measurement calliper tool. The CI ratio was calculated as the BPD multiplied by 100 and divided by the OFD. Mean, standard deviation (SD) and range were calculated for BPD, OFD and CI. Differences in measurements between demographic groups were compared using an unpaired *t*-test, with test  $\alpha$  set at 0.05. Of the population of Ghanaians included in this study, 165 (55%) were male and 135 (45%) were females. The mean CI was  $77.3 \pm 3.6$  in males and  $79.0 \pm 3.3$  in females, placing both genders in the mesocephalic category. However, the difference between males and females was found to be statistically significant ( $P=0.02$ ). The study indicated that most Ghanaian adults belong to the mesocephalic category of CI. Females also had a higher CI, which could be used to differentiate gender groups. This information can be useful for forensic medicine, plastic surgeries for clinical and research purpose.

### KEY POINTS

- This study found the mean CI of adult Ghanaians to be  $78.0 \pm 13.0$ .
- This indicates that most Ghanaian adults belong to the mesocephalic category of CI.
- Females had a higher CI, which could be used to differentiate gender groups.
- To the best of our knowledge, this is the first study which assessed CI of Ghanaians using CT scan.

### ARTICLE HISTORY

Received 20 November 2020  
Accepted 3 February 2021

### KEYWORDS

Forensic sciences; cranial index; CI; sexual dimorphism; computed tomography; CT

## Introduction

The cranial index (CI) (also known as the cephalic index) is a useful anthropological measure to help determine racial and sexual differences [1, 2]. The biometric features of the cranium can be used in the assessment of racial backgrounds, growth and development, and the diagnosis of any abnormalities in cranial size and shape within a population [3, 4]. In addition, CI can be particularly valuable in the identification of unknown remains in crime scene [5]. There are six classifications of CI which are summarised in Table 1.

Forensic anthropology is a difficult task, particularly when assessing human remains in an advanced stage of decomposition. In complex situations, such as the evaluation of human remains in a mass grave, it can be particularly useful to have metrics that

can be used to identify the victims as a particular race and gender, especially in countries like Ghana, where there is no national DNA database to rely on. The CI has also been found to help identify remains and provide cranial morphometry between parents and offspring which would help in the identification of genetic character transmission [1].

CI studies in countries like Japan, China, Nigeria, India and the USA among others, have classified their populations based on their average cranial indices [3, 7]. These developed indices have given them the advantage of using the CI as a reference point in forensic study and the study of sexual differences among individuals from different backgrounds. However, the CI has not been established for Ghanaian natives and it would be useful to help in planning of complex surgeries for craniofacial

**CONTACT** Benard Ohene Botwe [sirbenard13@gmail.com](mailto:sirbenard13@gmail.com); [bebotwe@ug.edu.gh](mailto:bebotwe@ug.edu.gh)

© 2021 The Author(s). Published by Taylor & Francis Group on behalf of the Academy of Forensic Science.

This is an Open Access article distributed under the terms of the Creative Commons Attribution License (<http://creativecommons.org/licenses/by/4.0/>), which permits unrestricted use, distribution, and reproduction in any medium, provided the original work is properly cited.

**Table 1.** The six classifications of the cranial index (CI) and the shape of the skull when viewed from the top [6], cited with permission.

Classification	CI	Shape
Hyperdolichocephalic	65.0–69.9	Long and narrow when seen from the top
Dolichocephalic	70.0–74.9	
Mesocephalic	75.0–79.9	Nearly oval when seen from the top
Brachycephalic	80.0–84.9	Broad and short skull when seen from the top
Hyperbrachycephalic	85.0–89.9	
Ultrabrachycephalic	90.0+	

injuries [8]. It could also be used in assessing the growth and development of individuals and in the diagnosis of abnormalities of cranial shape and size [4]. Though CI is an important marker in the evaluation of racial, gender differences and a supporting tool in medicine, little is known about the CI and its variations in Ghanaians.

This study uses a modern technology, computed tomography (CT), to measure the CI in a population of Ghanaians. Varying approaches have been used to establish CI, including measurement on dry bones, projectional X-ray imaging, and cross-sectional imaging [5] but the geometrical accuracy of transaxial CT images was preferred for this study [9, 10].

## Methods and materials

In accordance with established research protocols, ethical approval was granted by the Ethics and Protocols Review Committee of the School of Biomedical and Allied Health Sciences of the University of Ghana for the commencement of this study. Data collection was also approved by Korle Bu Teaching Hospital, where all images were acquired between 1st August 2018 and 30th April 2019. This is the largest hospital in Ghana, receiving referrals from all parts of the country.

## Patients

Sample size was determined using a calculation recommended by Charan and Biswas [11] to help generalise the results to the overall population of Ghana. Data from a total of 300 patients were collated using a systematic random sampling method. Only patients of 18 years and older were included in the study. Adult skull images were used because it was assumed that the skull vault has fused [12]. All patients were deemed to have a normal cranial image configuration based on the radiological report. Patients of foreign origin were excluded from the study. Demographic data, including sex and age of the sample were recorded. Names and personal identifiers were not recorded so that the data remained anonymous. No images were retained following measurement.

## Image acquisition & measurement

Images were acquired using a Toshiba Aquilion ONE CT scanner (Toshiba Medical Systems Corporation, Otawara, Japan) using a standard acquisition protocol. Details of the protocol used for the head CT procedures are presented in Table 2.

Measurements of the skull were performed on workstation software (Version 4.82, ER001) on transaxial image of the skull. The biparietal diameter (BPD, width), defined as the distance between most projecting points at either side of the skull, which is usually just superior and posterior to the external auditory meatus (EAM), and the occipitofrontal diameter (OFD, length), defined as the distance from the glabella to the most projecting point at the back of the skull. Both measurements were made using a digital calliper within the workstation software to calculate the CI, which is expressed as:  $CI = BPD / OFD \times 100$ .

## Data analysis

Data were recorded for all patients and descriptive statistics produced in Microsoft Excel<sup>®</sup>. Mean, standard deviation (SD) and range were calculated for BPD, OFD and CI. Differences in measurements between demographic groups (male and female) were compared using a Mann Whitney *U* test with differences considered to be statistically different at a test  $\alpha$  of 0.05. A Shapiro-Wilk test was used to assess normality of the data.

## Results

### Demographics and normality of data

Data from 300 CT Head images were used to generate the mean CI of Ghanaian nationals. Within our sample there were 165 males (55%) and 135 females (45%). The age range was 18–94 years with mean of  $(49.0 \pm 18.1)$  years old. A Kolmogorov-Smirnov test revealed that the age range of the sample was not normally distributed ( $P = 0.042$ , skewness = 0.11, kurtosis =  $-0.92$ ), therefore a Mann Whitney *U* Test was used for subsequent tests comparing males and females as it does make assumptions about

**Table 2.** The standard acquisition protocol used to perform the head computed tomography (CT) scans.

Acquisition parameter	Value
Tube current (kVp)	120
Tube current modulation	Sure exposure 3 D
Pitch	0.656
Rotation time (s)	0.75
Detector configuration	32 × 0.5
Scan range	Base of skull to vertex
Slice thickness (mm)	0.5

normality. The distribution of all subjects included can be found in Figure 1.

### BPD, OFD and CI

The mean BPD, OFD and CI values observed for the entire sample were  $(139.4 \pm 5.4)$  mm (range of 126.5–157.2 mm),  $(179.1 \pm 8.6)$  mm (range 157.6–201.3 mm) and  $78.0 \pm 13.0$  (range 67.4–92.6), respectively.

In relation to gender, the mean BPD, OFD and CI values obtained for males were  $(140.5 \pm 5.6)$  mm (range 126.5–157.2 mm),  $(182.0 \pm 8.5)$  mm (range 157.6–201.3 mm) and  $77.3 \pm 3.6$  (range 67.4–89.5), respectively. The female group also recorded mean BPD, OFD and CI values of  $(138.0 \pm 4.9)$  mm (range 129.1–152.2 mm),  $(175.6 \pm 7.4)$  mm (range 157.6–201.3 mm) and  $79.0 \pm 3.3$  (range 72.9–92.6), respectively.

In this study, the majority of measurements ( $n=163$ , 54.3%) were classified as mesocephalic. Others were: brachycephalic ( $n=71$ , 23.7%), dolichocephalic ( $n=53$ , 17.7%), hyperbrachycephalic ( $n=9$ , 3.0%), hyperdolichocephalic ( $n=3$ , 1.0%) and ultra-brachycephalic ( $n=1$ , 0.3%).

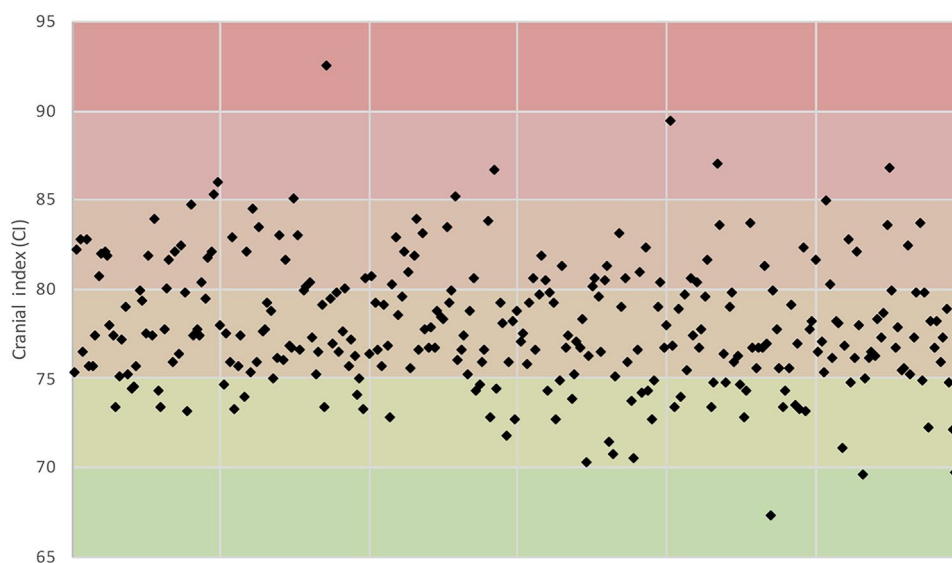
### Discussion

The cranium is the part of the skeleton that forms the cavity of the brain. A good knowledge of its morphology presents an important character in the determination of racial and gender differences [2, 13]. Apart from the CI being importance in forensic studies, it also crucial for the assessment of pre- and post-operative correction of skull deformations [9].

This study was aimed at determining the CI of Ghanaians using CT scan images. The CT images are considered a very accurate and good alternative in the absence of skeletal remains [14]. From the study, the mean CI was  $78.0 \pm 13.0$  to suggest that most of the participants were mesocephalic (CI of 75.0–79.9), with their skulls nearly oval [6].

The mean CI in males was  $77.3 \pm 3.6$  while that of females was  $79.0 \pm 3.3$  both being in the mesocephalic group. According to a study [15], differences are generally expected between males and females, with CI found to be larger in female. This result supports prior findings of other studies such as that of Munguti et al. [16], which produced CI of  $72.34 \pm 4.34$  in females and  $71.04 \pm 3.58$  in males. However, the findings in the present study contrast with that of Oladipo and Olotu [17], in which males of the Ijaw ethnic group in Nigeria were hyperbrachycephalic while females were mesocephalic. Oladipos et al.'s [13] findings on Ibibio tribe also indicated that Ibibio males had higher CI than females.

This study established the mean values of the CI for various age groups in both genders. The results showed the difference between the CI of the various age groups, with respect to gender. The difference was observed to be statistically insignificant in both males and females, respectively. This indicates that the various age groups all have almost the same CI. Moreover, there was no particular pattern between the age groups and their cranial indices. This result is in agreement with findings by Oladipo et al. [13] and Osunwoke et al. [18] on Ogonis and Ogu and Ikwerre ethnic groups, identifying no particular pattern between the age groups and cranial indices.



**Figure 1.** The distribution of all measurements of cranial index for the 300 subjects included in this study. As can be seen from this graphic, the majority of Ghanaians fall into the mesocephalic category (75.0–79.9).

## Conclusion

The study indicated that most Ghanaian adults belong to the mesocephalic category of CI. Females had a higher CI compared to their male counterparts, which could be used to differentiate gender groups. Particularly, the range of CI was observed to be 67.4–89.5 in males with a mean of  $77.3 \pm 3.6$  and a range of 72.9–92.6 in females with a mean of  $79.0 \pm 3.3$ . This information can be useful for forensic medicine, plastic surgeries for clinical and research purpose.

## Authors' contributions

Benard Ohene Botwe designed the study and contributed to the data analysis. Jeffrey Nana Afari Boadu collected and analysed the data. Kofi Adesi Kyei contributed to the study design and data analysis. John D. Thompson contributed to the data analysis. All authors participated in the drafting of the manuscript. All authors contributed to the final manuscript and approved it for publication.

## Compliance with ethical standards

The study was conducted in line with the standard set out by the Ethics and Protocols Review Committee of the School of Biomedical and Allied Health Sciences of the University of Ghana.

## Disclosure statement

No potential conflict of interest was reported by the authors.

## ORCID

Benard Ohene Botwe  <http://orcid.org/0000-0002-0477-640X>  
Kofi Adesi Kyei  <http://orcid.org/0000-0003-3485-5368>  
John D. Thompson  <http://orcid.org/0000-0002-4786-7379>

## References

- [1] Shah GV, Jadhav HR. The study of cephalic index in students of Gujarat. *J Anat Soc India*. 2004;53:25–26.
- [2] Williams P, Dyson M, Dussak JE, et al. *Gray's anatomy*. 38th Ed. London (UK): Elbs with Churchill Livingstone; 1995. p. 607–612.
- [3] Krishan K, Chatterjee PM, Kanchan T, et al. A review of sex estimation techniques during examination of skeletal remains in forensic anthropology casework. *Forensic Sci Int*. 2016;261:165.e1–e8.
- [4] Llayperuma I. Evaluation of cephalic indices: a clue for racial and sex diversity. *Int J Morphol*. 2011;29:112–117.
- [5] Mehta M, Saini V, Nath S, et al. CT scan images to determine the origin from craniofacial indices for Gujarati population. *J Forensic Radiol Imaging*. 2014;2:64–71.
- [6] Kumari K, Babu P, Kumari P, et al. A study of cephalic index and facial index in Visakhapatnam, Andhra Pradesh, India. *Int J Res Med Sci*. 2015;3:656–658.
- [7] Yagain VK, Pai SR, Kalthur SG, et al. Study of cephalic index in Indian students. *Int J Morphol*. 2012;30:125–129.
- [8] Marcus JR, Domeshek LF, Loyd AM, et al. Use of a three-dimensional, normative database of pediatric craniofacial morphology for modern anthropometric analysis. *Plast Reconstr Surg*. 2009;124:2076–2084.
- [9] Musa MA, Danfulani M. Cranial index determination using computed tomography (CT) scans of children with normal brain development: a retrospective study. *Cukurova Med J*. 2015;40:239–244.
- [10] Ramsthaler F, Kettner M, Gehl A, et al. Digital forensic osteology: morphological sexing of skeletal remains using volume-rendered cranial CT scans. *Forensic Sci Int*. 2010;195:148–152.
- [11] Charan J, Biswas T. How to calculate sample size for different study designs in medical research? *Indian J Psychol Med*. 2013;35:121–126.
- [12] Igbigbi PS, Ebite LE. Orbital index of adult Malawians. Anil Aggrawal's *Int J Forensic Med Toxicol*. 2010. 11. Available from: [http://www.anilaggrawal.com/ij/vol\\_011\\_no\\_001/papers/paper001.html](http://www.anilaggrawal.com/ij/vol_011_no_001/papers/paper001.html)
- [13] Oladipo GS, Olotu JE, Suleiman Y. Anthropometric studies of cephalic indices of the Ogonis in Nigeria. *Asian J Med Sci*. 2009;1:15–17.
- [14] Cavalcanti M, Rocha S, Vannier M. Craniofacial measurements based on 3D-CT volume rendering: implications for clinical applications. *Dentomaxillofac Radiol*. 2004;33:170–176.
- [15] Woo EJ, Jung H, Tansatit T. Cranial index in a modern people of Thai ancestry. *Anat Cell Biol*. 2018;51:25–30.
- [16] Munguti J, Mandela P, Butt F. Sex differences in the cranial and orbital indices for a black Kenyan population. *Int J Med Med Sci*. 2013;5:81–84.
- [17] Oladipo GS, Olotu EJ. Anthropometric comparison of cephalic indices between the Ijaw and Igbo tribes. *Global J Pure Appl Sci*. 2006;12:137–138.
- [18] Osunwoke EA, Oladipo GS, Ordu KS, et al. Anthropometric study of the cephalic and nasal indices of Ogu and Ikwerre people of Nigeria. *Curr Res J Biol Sci*. 2012;4:1–3.