

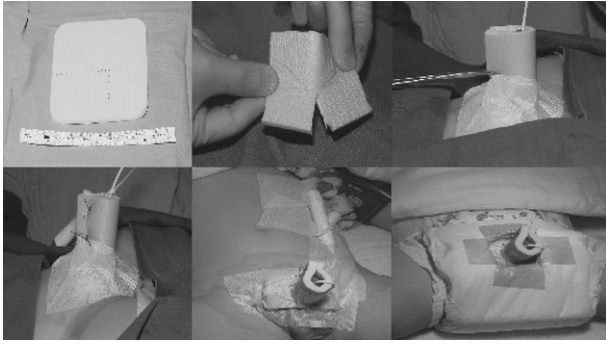Figure 1 Application of a non-adherent, tri-laminate (Allevyn) dressing.

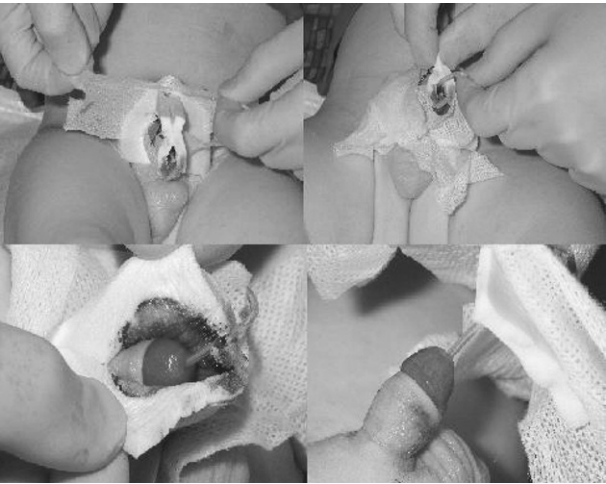


Figure 2 Dressing removal.

dressing should also be easy to remove with the least discomfort and distress to the patient and their family. Most dressings are bulky, hard to apply or remove, and may fall off in an active child.¹⁻³ We describe a dressing using Allevyn (Smith & Nephew Healthcare, Healthcare House, Hull, UK).

TECHNIQUE

The lower end of dressing is split to form two equal lateral flaps which will sit on the pubo-scrotal area and secure with adhesive plaster. The rest of the dressing is rolled into a cylindrical shape wrapping round the penile shaft and is closed on the dorsal aspect using two interrupted silk stitches. The top end of the dressing is left open to allow the urinary catheter to come through (Fig. 1). Removal of the dressing is carried out after either 2 or 5 days depending on the type of repair. The plaster is sprayed with an alcohol-based disinfectant and stitches are cut. The dressing, being non-adherent, is easily separated off from the wound (Fig. 2).

DISCUSSION

Allevyn has a unique tri-laminate structure, inner non-adherent, central absorbent and outer water- and microbial-proof layers. None of the 85 dressings after repair (63 Mathieu's, 11 Duckett's and 11 Bracka's) dislodged prematurely. All dressings were

removed on the ward with minimal distress to the patients. There was no early wound infection. This non-adherent and tri-laminate dressing is simple to apply and compatible with early discharge from hospital.⁴

References

1. Cilento Jr BG, Stock JA, Kaplan GW. Pantaloon spica cast: an effective method for postoperative immobilisation after free graft hypospadias repair. *J Urol* 1997; **157**: 1882-3.
2. Whitaker RH, Dennis MJ. Silastic foam dressing in hypospadias surgery. *Ann R Coll Surg Engl* 1997; **69**: 59-60.
3. Davalbhakta A, Summerlad BC. Cavi-Care dressing for hypospadias repair. *Br J Plast Surg* 1999; **52**: 325-6.
4. Grobbelaar AO, Laing JH, Harrison DH, Sanders R. Hypospadias repair: the influence of postoperative care and a patient factor on surgical morbidity. *Ann Plast Surg* 1996; **37**: 612-7.

L-Configuration re-attachment of distal biceps tendon rupture

CP CHARALAMBOUS¹, TK GULLETT¹, N PHILIPS², L FUNK³, MJ RAVENSCROFT¹

¹Dept Shoulder and Elbow Surgery, Stepping Hill Hospital, Stockport, UK

²Dept Upper Limb Surgery, Wythenshawe Hospital, Manchester, UK

³Dept of Upper Limb Surgery, Wrightington Hospital, Wigan, UK

CORRESPONDENCE TO

CP Charalambous, Department of Shoulder and Elbow Surgery, Stepping Hill Hospital, Poplar Grove, Hazel Grove, Stockport SK2 7JE, UK. E: bcharalambos@hotmail.com

BACKGROUND

In distal biceps tendon ruptures, re-attachment to the radial tuberosity should ensure adequate tendon to bone contact for optimal healing.

TECHNIQUE

Using a transverse incision at the cubital crease, we dissect to the radial tuberosity into which two suture anchors (5.0 mm FASTIN RC, Mitek, UK or 3.5 mm Twinfix, Smith-Nephew, UK) are inserted, each with two suture strand pairs. The tendon is held outside the wound during suture passing. Each pair of distal anchor sutures (Fig. 1, X1) is passed through the distal part of the tendon. One strand is passed in a zigzag fashion through the tendon (Fig. 1, C and D) whilst the other (Fig. 1, A and B) is passed straight posterior to anterior. The four strands of the proximal anchor (Fig. 1, X2) are passed to form two mattress sutures through the proximal tendon when tied (Fig. 1, E and F). Tightening is performed in a specific sequence, initially pulling on strands A and B to position tendon to bone, and then tightening these to the corresponding suture strand of their pair. The two suture pairs are tied to each other. Following this, the mattress sutures of the proximal anchor are tied individually and then over the tendon to each other, creating a box type pattern. The second

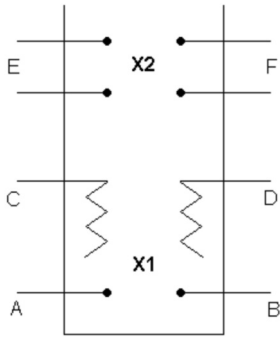


Figure 1 Anterior to posterior view of the biceps tendon repair. A, C and B, D refer to the two suture strand pairs from the distal anchor, X1. E and F refer to the two strand pairs from the proximal anchor X2.

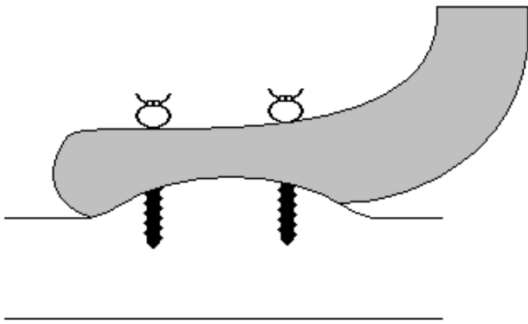


Figure 2 Lateral view of the biceps tendon showing its L-shaped re-attachment to the radial tuberosity using bone anchors.

anchor sutures are then tightened bringing tendon down onto the bone in an L-configuration (Fig. 2).

DISCUSSION

The technique is simple to perform, provides a sound repair, and ensures a large tendon-to-bone surface contact. We have performed this in 25 patients with no cases of tendon re-rupture.

'Laser avulsion'

R DURAI, C KYRIAKIDES

Dept of Vascular and Endovascular Surgery, Barts and The London NHS Trust, The Royal London Hospital, London, UK

CORRESPONDENCE TO

C Kyriakides, Consultant Vascular and Endovascular Surgeon, Barts and The London NHS Trust, The Royal London Hospital, London E1 1BB, UK. T: + 44 (0)20 7377020; F: + 44(0)20 7377684; E: constantinos.kyriakides@bartsandthelondon.nhs.uk

BACKGROUND

Varicose vein due to superficial venous insufficiency is a common problem world-wide^{1,2} and endovenous laser ablation (EVLA) has been used for treatment for at least 6 years.³ Skin burn and

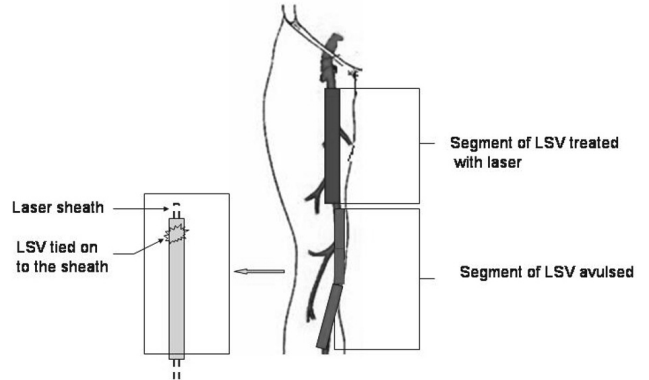


Figure 1 'Laser avulsion' which is a novel combination of laser ablation of proximal long saphenous vein (LSV) and avulsion of the distal thigh and knee segments of LSV. After laser ablation, the laser fibre is removed and the vein is tied on to the sheath. The lower shaded segment of vein is avulsed by pulling the sheath.

permanent staining can occur when the laser ablation is used for veins which are in very close proximity to the skin⁴ particularly in thin, fairer individuals without much subcutaneous fat. While performing EVLA in these patients, it may be difficult to push the distal vein away from the skin with tumescent.

TECHNIQUE

The authors describe a new technique, which is a novel combination of EVLA of the proximal superficial vein and stripping or avulsion of the distal vein (Fig. 1). The authors call this technique 'laser avulsion'. Because there is enough fat in the thigh and the long saphenous vein (LSV) is deep seated, EVLA of the proximal LSV segment can be safely undertaken. In the distal thigh and around the knee where the vein can be close to the skin, one can make a small (2 mm) cut down on to the vein, remove the laser fibre but leave the sheath *in situ* and tie the vein secure to the laser sheath. The ablated vein is then disconnected proximally and the sheath is pulled out with the distal segment of the non-ablated vein. Therefore, the proximal thigh segment of the LSV is laser ablated and lower thigh, knee and upper leg segment of the vein is stripped.

DISCUSSION

The advantage of this procedure is one can avoid both the groin incision of the Trendelenburg procedure and potential permanent discoloration and skin burn of the lower aspect of superficial vein which may happen in EVLA.

References

1. Campbell B. Varicose veins and their management. *BMJ* 2006; **333**: 287–92.
2. London NJ, Nash R. ABC of arterial and venous disease. Varicose veins. *BMJ* 2000; **320**: 1391–4.
3. Min RJ, Zimmet SE, Isaacs MN, Forrestal MD. Endovenous laser treatment of the incompetent greater saphenous vein. *J Vasc Intervent Radiol* 2001; **12**: 1167–71.
4. Durai R, Srodon PD, Kyriakides C. Endovenous laser ablation for superficial venous insufficiency. *Int J Clin Pract* 2008 [Epub ahead of print].