

The accuracy of Cobb angle measurement on CT scan projection radiograph images.

Faisal Alrehily^{1,2}

Peter Hogg²

Martin Twiste²

Safora Johansen^{3,4}

Andrew Tootell²

¹ *College of Applied Medical Sciences, Taibah University, Medina 42353, Saudi Arabia.*

² *School of Health and Society, University of Salford, Salford M5 4WT, United Kingdom.*

³ *Oslo Metropolitan University, Faculty of Health Sciences, Norway.*

⁴ *Department of Oncology, Division of Cancer Medicine, Surgery and Transplantation, Oslo University Hospital, Radiumhospitalet, Oslo, Norway.*

Abstract

Introduction: Adolescent idiopathic scoliosis (AIS) is a spinal deformity that can affect young children. It requires frequent exposure to X-rays to monitor the deformity, which can lead to the development of radiation-induced cancer later in life. The aim of this study is to test the accuracy of using scan projection radiography (SPR) in computed tomography (CT) scans for AIS assessment. This scanning mode delivers low radiation compared with conventional radiography.

Method: A bespoke phantom with a 14° scoliotic spine was scanned in CT SPR mode using 18 imaging acquisitions. These images were visually evaluated against set criteria to determine their suitability for Cobb angle measurements. Those deemed of insufficient quality were excluded from the study (n=8, excluded). Cobb angle measurements were then performed on the remaining images (n=10, included) by 13 observers.

Results: On average, the difference between the measured Cobb angle and the known angle was -2.75° (SD 1.46°). The agreement between the observers was good ($p = 0.861$, 95% CI 0.70-0.95) and comparable to similar studies on other imaging modalities which are used for Cobb angle estimation.

Conclusion: CT SPR images can be used for AIS assessment with the 5° margin of error that is clinically acceptable.

Implications for practice: The outcome is promising for patients and health providers because it provides an opportunity to reduce patient dose, achieve clinically acceptable Cobb angle measurements whilst using existing (CT) technology that is available in most hospitals.

Introduction

Adolescent idiopathic scoliosis (AIS) is a complex three-dimensional spinal deformity. Its causes are unknown, and it predominately affects young females.^{1,2} In most cases, AIS, does not require treatment; instead, it is monitored until the patient matures. The monitoring process requires frequent radiological examination of the spine, which might occur at 3 to 12 months intervals depending on the severity of the curvature, the patient's age and the management plan.³ The X-ray images are used to determine the severity of deformity through Cobb's method⁴, which requires locating the endplates of the most tilted vertebrae to measure the angle between them. This is done by drawing a line on the superior endplate on the superior most tilted vertebra and another line on the inferior endplate of the inferior most tilted vertebra to measure the angle between them.

AIS patients are at risk of developing radiation-induced cancer later in life due to frequent exposure to X-rays. Mainly because of their young age, patients are expected to have long lifespans, and radiation-induced cancer has a long latency period that can be measured in decades.⁵⁻⁷ The risk is also higher because of the rapid changes their bodies undergo at this age, particularly in the breast tissue of young females.⁸ Much effort has been made to develop new imaging techniques for AIS assessment to reduce the risk of radiation to patients and improve the outcomes of the examination.

Our previous work⁹, in which we analysed radiation doses for scan projection radiograph (SPR), digital radiography (DR) and dedicated system EOS (EOS imaging system, Paris, France), has shown that SPR imaging protocols delivered varying levels of radiation dose. In comparison with the DR and EOS, SPR doses were comparable with, or even lower than, those of other X-ray imaging machines at selected imaging acquisitions. The risk of developing radiation-induced cancer for 10-year-old female patient when using SPR for AIS

assessment range from 0.14 - 7.9 cases per 10^6 , depending on the imaging protocol.⁹ In comparison, the risk from using the DR and EOS are 0.92- 2.26 cases per 10^6 and 0.07-0.86 cases per 10^6 , respectively⁹. Optimising SPR mode can lead to a potential dose reduction without the need for capital outlay on X-ray machines dedicated to Cobb angle assessment, e.g. EOS. Training is also minimised, compared with using dedicated systems, since CT scanners are already available in most hospitals.

The use of the SPR mode in CT is limited because of the absence of the gravitational effect on the morphology of the spine, which is not ideal for AIS assessment. However, the validity of assessing AIS in a non-weight bearing position is already proven in a study carried out by Lee et al.¹⁰. That research showed that their method allows the conversion of Cobb angle measurements from a magnetic resonance imaging (MRI) image to X-ray measurements by correlating the measurements of non-weight bearing positions to standing measurements. In turn, Wessberg, Danielson and Willen found that Cobb angle measurements in a supine position are comparable to measurements in an upright position when using a supporting device (i.e., an axial load device).¹¹ However, it is worth noting that there are CT systems that permit standing position, such as Onsite 3D Extremity System (Carestream Health, Rochester, NY, USA)^{12,13}

The aim of this work was to assess the accuracy of CT scan projection radiography (SPR) mode (commonly referred to as the “scout” view) for the assessment of AIS in a phantom representing a 10-year old. This scanning mode has been shown in previous work to be capable of delivering a radiation dose that is comparable with, or even lower than, that of the currently used X-ray technology, namely convention radiography (DR) and EOS.⁹

Method

A bespoke anthropomorphic phantom with the characteristics of a 10-year old AIS patient was created and validated with a known lateral curvature of Cobb angle 14° (Figure 1). This was imaged using CT SPR mode with the range of imaging parameters listed in Table 1.

These parameters included all possible options that the CT scanner was capable of in SPR mode. These imaging protocols were used in our previous work⁹, in which the radiation dose from SPR was quantified and compared with the dose from using the conventional radiography and EOS from assessing AIS.

Imaging protocol	Imaging projection	kVp	mA
CT1	AP	120	10
CT2	AP	120	20
CT3	AP	120	30
CT4	PA	120	10
CT5	PA	120	20
CT6	PA	120	30
CT7	AP	100	10
CT8	AP	100	20
CT9	AP	100	30
CT10	PA	100	10
CT11	PA	100	20
CT12	PA	100	30
CT13	AP	80	10
CT14	AP	80	20
CT15	AP	80	30
CT16	PA	80	10
CT17	PA	80	20
CT18	PA	80	30

As the images were intended for Cobb angle measurements, only frontal projections (i.e., anteroposterior (AP) and posteroanterior (PA)) were acquired in total, 18 images were acquired. As indicated in **Error! Reference source not found.**, each image was assigned a code (CT1-18) so that, when evaluated later, observers could be blinded to the imaging parameters. Imaging was conducted on a third-generation 16-slice CT scanner

(Toshiba Aquilion; Toshiba Medical Systems, Tokyo, Japan), and all quality control tests fell within manufacturer tolerances outlined in Institute of Physics and Engineering in Medicine (IPEM) Report 91.¹⁴

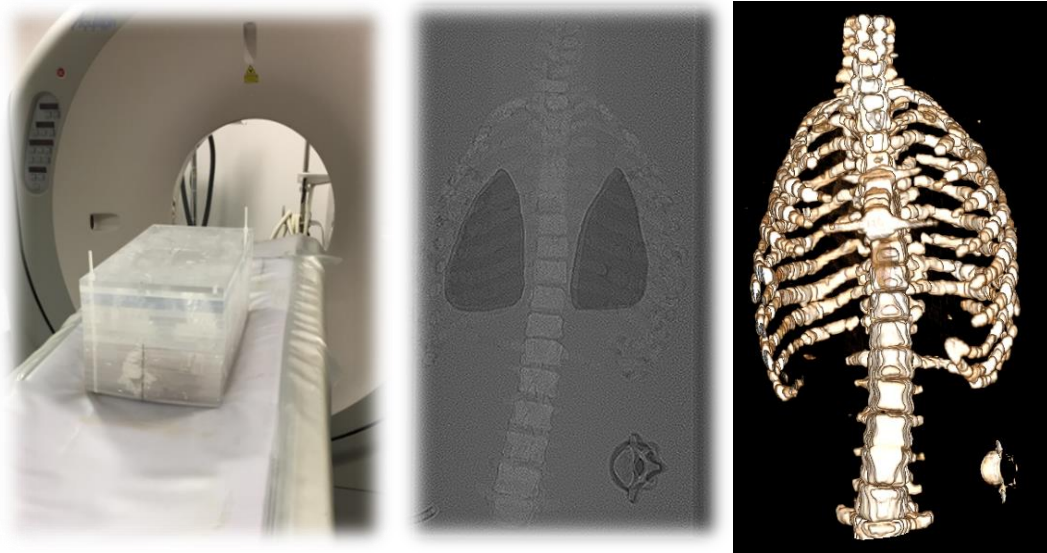


Figure 1: The phantom on the CT table (left); an AP projection image of the phantom acquired using SPR mode (middle); and a 3D image of the phantom (right).

Visual evaluation

Ethical approval for Cobb angle evaluation was obtained because volunteers would be used to make Cobb angle measurements on the images. After the 18 images had been acquired, they were inspected visually, using a grading scale, to identify which images were of suitable quality for Cobb angle measurements to be performed. A 5-megapixel monochrome reporting monitor (DOME E5, NDSsi, Santa Rosa, CA, USA), calibrated to the DICOM greyscale standard, was used for displaying the images.¹⁵

Using the grading scale, two radiographers, with over two years' experience, and two medical physicists, with experience in evaluating medical images through their work in radiation dose optimisation, evaluated the clarity of the endplates based on the European guidelines on quality criteria for diagnostic radiographic images.¹⁶ These guidelines recommend evaluating

seven anatomical features: 1) upper and lower plates surfaces; 2) pedicles; 3) intervertebral joints; 4) spinous and transverse processes; 5) cortex and trabecular structures; 6) adjacent soft tissue and 7) sacroiliac joints. These criteria are not specific to scoliosis imaging but general to spinal imaging. Therefore, most of the anatomical features are irrelevant to Cobb angle measurement, which was the purpose of this study. Consequently, the observers were asked to evaluate the appearance of the upper and lower endplates of all vertebrae in the images. The evaluation involved a visual grading scale, similar to that used in Alqaroot¹⁷: if an endplate was not clear in the image, then the entire image would be marked as unsuitable for Cobb angle measurements. Instead, only images that had been marked as suitable for Cobb measurements by all four observers were selected for the next stage (i.e. if there was disagreement, the images were not included in the study). The use of this scale ensured that only images with adequate quality for Cobb angle measurements were included for the next stage of the study.

Cobb angle measurements

Thirteen observers (seven diagnostic radiographers and six orthotist) were invited to perform Cobb angle measurements. The Cobb angle was measured digitally using Radiant image viewer software (Mediavxnt, Poznan, Poland). The observers' levels of experience varied: the radiographers had at least two years' experience, whereas the orthotists included four students (one first year and three third year) and two academic members of staff. Despite the level of experience, all observers were given the same ½ hour training session to ensure that they were familiar with the measuring software and, importantly, how to place 'lines' on the image in order to calculate Cobb angle.

In the training sessions, which were delivered individually to each observer before the Cobb angle was measured, the basic concepts of the Cobb method were explained, and the

observers were familiarised with the software. Part of the Cobb method is identifying the most tilted vertebrae; therefore, the observers were trained to identify these vertebrae. To do so, they had to select all possible tilted vertebrae and perform the Cobb method on each two vertebrae. For example, if they selected T5 and T6 as the most tilted superior vertebrae, and L1 and L2 as the most tilted inferior vertebrae, they had to perform the angle measurements four times as follows: T5 and L1, T5 and L2, T6 and L1 and T6 and L2. The measurements were then compared, and the pair of vertebrae with the largest angle were selected as the most tilted vertebrae. This step was introduced to increase the accuracy of the measurements and to ensure that it was indeed the most tilted vertebrae that were selected.

The second part of the training session was to practice performing the measurements on two conventional radiography images that had been downloaded from an online library and anonymised of patients with AIS.¹⁸ After finishing the training session, the observers were asked to identify the most tilted vertebrae and determine the degree of the curve in the phantom images. The observers were blinded to the imaging parameters, and the measurements were performed once in an attempt to reflect clinical practice and increase the validity of the outcomes.

Data analysis

The number of observers (sample size) needed for the study was determined using G*power¹⁹, with 90% power to detect the difference from a constant with an α -error of 5%. The consistency of the observers' image evaluations and Cobb angle measurements was determined using an intra-class correlation (ICC) two-way mixed model. The ICC demonstrates the degree of correlation and agreement between the measurements with ICC < 0.5 indicating poor reliability, between 0.5 and 0.74 indicating moderate reliability, between 0.75 and 0.89 indicating good reliability and an ICC > 0.90 indicates excellent reliability.^{20,21}

The measured Cobb angle was subtracted from the known angle of the phantom (14°) to find the difference between the two angles.

Results

Visual evaluation

Using the visual grading scale, 10 images out of the 18 were identified as suitable for Cobb angle measurements based on the clarity of the endplates. The 10 images that produced acceptable image quality are shown in Table 3. The inter-observer agreement was good, as the ICC value was 0.76, with a 95% confidence interval (CI) between 0.60 and 0.86.

Cobb angle measurements

Table 2 shows a summary of Cobb angle measurements for the two training images. The inter-observer variation is within the 5°, except for observers one and ten within image two. On the SPR images, the average difference from the true angle of the phantom spine (14°) was -2.75° (SD=1.46°), and the agreement between the observers (ICC) was good at 0.861 (95% CI 0.70-0.95). Table 3 reports the measured Cobb angle in each image.

Observer	Image 1	Image 2
1	87.1°	45.7°
2	89.8°	54.5°
3	88.1°	51.7°
4	87.9°	50.1°
5	88.4°	50.9°
6	88.2°	53.4°
7	87.6°	52.2°
8	88.2°	50.4°
9	88.7°	53°
10	85.7°	47.8°
11	85.5°	49.9°
12	88.6°	53.4°
13	88°	45°
Average	87.8	50.6
SD	1.2	2.9

Imaging protocol	CT3	CT4	CT5	CT6	CT8	CT9	CT10	CT11	CT12	CT15
Projection	AP	PA	PA	PA	AP	AP	PA	PA	PA	AP
kVp	120	120	120	120	100	100	100	100	100	80
mA	30	10	20	30	20	30	10	20	30	30
Average angle	9.84	11.31	14.91	11.69	11.48	10.28	9.74	11.15	10.53	11.48
SD	2.81	1.30	1.69	1.50	2.38	1.93	1.30	1.62	2.12	1.85

Discussion

In this paper, we aimed to assess the accuracy of CT SPR mode for the assessment of AIS in a bespoke anthropomorphic phantom representing a 10-year old with AIS. The results from our study suggest that CT SPR images can be used for AIS evaluation using Cobb angle, with an acceptable variation of 5° between the observers which is clinically acceptable.²²⁻²⁵ This variation represents 95% of a true difference between two measurements²⁶. Thus, Cobb's Method is associated with variation in the measurements; an average of 6.34°, 3.62°, 2.1° and 3.75° difference in Cobb angle measurements have been reported in recent studies.^{25,27,28} The findings of our work are in agreement with published differences. It is worth mentioning that the measurements arising from our work were compared with a known angle of the curved spine, unlike previous published works, where only the difference between the measurements of the observers was compared.

The agreement between the observers of Cobb angle measurements is comparable to the results published in the Langensiepen (2013) review²⁹ and other published works too^{30,31}, with an ICC range between 0.83 and 0.99. However, when comparing the Cobb angle measurements with the known angle of the phantom spine, it seems that the angle was underestimated in 9 out of 10 images. The underestimation in the measurements could be

linked to the variation in the quality of the images and the large inter-observer variability of the Cobb method and how it can affect measurements.

The findings of our work suggest that SPR mode in CT scan has the potential of reducing patient dose when used for AIS assessment compared with the currently used machines, namely the digital radiography (DR) and EOS. In the previous work⁹, we investigated the dose levels from using SPR, DR (DR) and EOS for assessing AIS. The dose reduction in SPR was not at the same level to that which can be achieved using EOS imaging systems. However, EOS imaging systems are not widely available, and their use is limited compared with other imaging systems, especially outside of specialised paediatric centres. TablesTable 4Table 5 show the effective dose of the imaging protocols used in this work and of the DR and ESO when used to assess AIS.

Imaging protocol	CT3	CT4	CT5	CT6	CT8	CT9	CT10	CT11	CT12	CT15
Projection	AP	PA	PA	PA	AP	AP	PA	PA	PA	AP
kVp	120	120	120	120	100	100	100	100	100	80
mA	30	10	20	30	20	30	10	20	30	30
Effective dose (mSv)	0.25	0.02	0.04	0.10	0.06	0.16	0.01	0.02	0.06	0.10

Imaging machine	DR	DR	EOS	EOS
Imaging projection	AP	PA	AP+lateral	AP
Effective dose (mSv)	0.08	0.03	0.03	0.01
The imaging parameters used for radiation dose measurements are published in our previous work ⁹ .				

Our work is not without limitations. For example, the relationship between the image quality and the accuracy of the Cobb angle measurements was not established due to the lack of SPR images using the same imaging acquisitions, and the lack of repeated Cobb angle

measurements. A further possible limitation surrounds the use of supine, rather than erect, imaging. However as demonstrated in our paper, previous research suggests that following a mathematical correction supine imaging can offer a fairly accurate alternative to erect imaging; additionally, as CT scanners that allow erect imaging to start to be installed the potential problem of [only] supine imaging would disappear.

Conclusion

We propose that SPR has the potential to be used in the assessment of AIS in 10-year-old children. Prior to implementing our recommendation into practice, it is essential that optimisation is conducted to identify which SPR imaging parameters result in the most accurate Cobb angle results along with a low dose. Overall, the outcome of our work is promising for patients and health providers because it provides an opportunity to reduce patient dose, achieve clinically acceptable Cobb angle measurements whilst using existing (CT) technology that is available in most hospital settings; the latter, of course, could be important in a cost-challenged healthcare environment.

References

1. Trobisch P, Suess O, Schwab F. Idiopathic scoliosis. *Dtsch Arztebl Int* [Internet]. 2010;107(49):875-883; Available from: <http://www.pubmedcentral.nih.gov/articlerender.fcgi?artid=3011182&tool=pmcentrez&rendertype=abstract>
2. Kim H, Kim HS, Moon ES, Yoon C, Chung T-S, Song H-T, et al. Scoliosis Imaging : What Radiologists Should Know. *Main* [Internet]. 2010;30(2006):1823–42. Available from: <http://www.ncbi.nlm.nih.gov/pubmed/21057122>
3. Presciutti SM, Karukanda T, Lee M. Management decisions for adolescent idiopathic scoliosis significantly affect patient radiation exposure. *Spine J* [Internet]. 2014;14(9):1984–90. Available from: <http://dx.doi.org/10.1016/j.spinee.2013.11.055>
4. Cobb J. Outline for the study of scoliosis. *Am Acad Orthop Surg*. 1948;5:261–75.
5. National Research Council. *Analysis of Cancer Risks in Populations Near Nuclear Facilities: Phase 1* [Internet]. Washington, DC: The National Academies Press; 2012. Available from: <https://www.nap.edu/catalog/13388/analysis-of-cancer-risks-in-Populations-near-nuclear-facilities-phase>
6. Carpenter DO, Bushkin-Bedient S. Exposure to chemicals and radiation during childhood and risk for cancer later in life. *J Adolesc Heal* [Internet]. 2013;52(5 SUPPL):S21–9. Available from: <http://dx.doi.org/10.1016/j.jadohealth.2013.01.027>
7. Shuryak I, Hahnfeldt P, Hlatky L, Sachs RK, Brenner DJ. A new view of radiation-induced cancer: Integrating short- and long-term processes. Part II: Second cancer risk estimation. *Radiat Environ Biophys*. 2009;48(3):275–86.

8. Ronckers CM, Erdmann CA, Land CE. Radiation and breast cancer: a review of current evidence. *Breast Cancer Res* [Internet]. 2005;7(1):21–32. Available from: <http://www.pubmedcentral.nih.gov/articlerender.fcgi?artid=1064116&tool=pmcentrez&rendertype=abstract>
9. Alrehily F, Hogg P, Twiste M, Johansen S, Tootell A. Scoliosis imaging: An analysis of radiation risk in the CT scan projection radiograph and a comparison with projection radiography and EOS. *Radiography* [Internet]. 2019; Available from: <http://www.sciencedirect.com/science/article/pii/S1078817419300124>
10. Lee MC, Solomito M, Patel A. Supine magnetic resonance imaging Cobb measurements for idiopathic scoliosis are linearly related to measurements from standing plain radiographs. *Spine (Phila Pa 1976)*. 2013;38(11).
11. Wessberg P, Danielson BI, Willen J. Comparison of Cobb angles in idiopathic scoliosis on standing radiographs and supine axially loaded MRI. *Spine (Phila Pa 1976)*. 2006;31(26):3039–44.
12. Gang GJ, Zbijewski W, Mahesh M, Thawait G, Packard N, Yorkston J, et al. Image quality and dose for a multisource cone-beam CT extremity scanner. *Med Phys* [Internet]. 2018 Jan 1;45(1):144–55. Available from: <https://doi.org/10.1002/mp.12659>
13. Barg A, Bailey T, Richter M, De Cesar Netto C, Lintz F, Burssens A, et al. Weightbearing Computed Tomography of the Foot and Ankle: Emerging Technology Topical Review. *Foot Ankle Int*. 2018;39(3):376–86.
14. IPEM. Recommended Standards for the Routine Performance Testing of Diagnostic X-Ray Imaging Systems. 2nd ed. Hiles P, editor. Institute of Physics and Engineering in Medicine; 2014.

15. RCR. Picture archiving and communication systems (PACS) and guidelines on diagnostic display devices Third edition [Internet]. *Clinical Radiology*. 2019. Available from:
https://www.rcr.ac.uk/system/files/publication/field_publication_files/bfcr192_pacs-diagnostic-display.pdf
16. CEC. European guidelines on quality criteria for diagnostic radiographic images: report EUR 16260 EN. Luxembourg: Office for Official Publications of the European Communities; 1996. 1–88 p.
17. AlQaroot B. The Effects of Body Fat Percentage on Inter-Vertebral Spinal Mobility Control from Hyperextension Spinal Orthoses. University of Salford, Salford, UK; 2012.
18. Science Photo Library Limited. Science photo library [Internet]. 2018 [cited 2018 Oct 3]. Available from: <https://www.sciencephoto.com/media/946253/view/scoliosis-x-ray>
19. Faul F, Erdfelder E, Buchner A. G*Power 3: A flexible statistical power analysis program for the social, behavioral, and biomedical sciences. *Behav Res Methods*. 2007;39(2):175–91.
20. Portney L, Watkins M. *Foundations of clinical research: applications to practice*. New Jersey: Prentice Hall; 2000.
21. Koo TK, Li MY. A Guideline of Selecting and Reporting Intraclass Correlation Coefficients for Reliability Research. *J Chiropr Med [Internet]*. 2016;15(2):155–63. Available from: <http://doi.org/10.1016/j.jcm.2016.02.012>
22. Shea KG, Stevens PM, Nelson M, Smith JT, Masters KS, Yandow S. A comparison of manual versus computer-assisted radiographic measurement. *Intraobserver*

- measurement variability for Cobb angles. *Spine (Phila Pa 1976)*. 1998 Mar;23(5):551–5.
23. Carman DL, Browne RH, Birch JG. Measurement of scoliosis and kyphosis radiographs. Intraobserver and interobserver variation. *J Bone Joint Surg Am*. 1990 Mar;72(3):328–33.
 24. Cracknell J, Lawson DM, Taylor JA. Intra- and inter-observer reliability of the Cobb measurement by chiropractic interns using digital evaluation methods. *J Can Chiropr Assoc [Internet]*. 2015 Sep;59(3):261–8. Available from: <https://www.ncbi.nlm.nih.gov/pubmed/26500360>
 25. Lechner R, Putzer D, Dammerer D, Liebensteiner M, Bach C, Thaler M. Comparison of two- and three-dimensional measurement of the Cobb angle in scoliosis. *Int Orthop*. 2017;41(5):957–62.
 26. Chung N, Cheng YH, Po HL, Ng WK, Cheung KC, Yung HY, et al. Spinal phantom comparability study of Cobb angle measurement of scoliosis using digital radiographic imaging. *J Orthop Transl [Internet]*. 2018;15:81–90. Available from: <https://doi.org/10.1016/j.jot.2018.09.005>
 27. Gstoettner M, Sekyra K, Walochnik N, Winter P, Wachter R, Bach CM. Inter- and intraobserver reliability assessment of the Cobb angle: Manual versus digital measurement tools. *Eur Spine J*. 2007;16(10):1587–92.
 28. Chan ACY, Morrison DG, Nguyen D V., Hill DL, Parent E, Lou EHM. Intra- and interobserver reliability of the cobb angle-vertebral rotation angle-spinous process angle for adolescent idiopathic scoliosis. *Spine Deform [Internet]*. 2014;2(3):168–75. Available from: <http://dx.doi.org/10.1016/j.jspd.2014.02.006>

29. Langensiepen S, Semler O, Sobottke R, Fricke O, Franklin J, Schönau E, et al. Measuring procedures to determine the Cobb angle in idiopathic scoliosis: A systematic review. *Eur Spine J.* 2013;22(11):2360–71.
30. Brink RC, Schlösser TPC, Colo D, Vincken KL, van Stralen M, Hui SCN, et al. Asymmetry of the Vertebral Body and Pedicles in the True Transverse Plane in Adolescent Idiopathic Scoliosis: A CT-Based Study. *Spine Deform.* 2017;5(1):37–45.
31. Bagheri A, Liu XC, Tassone C, Thometz J, Tarima S. Reliability of Three-Dimensional Spinal Modeling of Patients With Idiopathic Scoliosis Using EOS System. *Spine Deform* [Internet]. 2018;6(3):207–12. Available from: <https://doi.org/10.1016/j.jspd.2017.09.055>